Frontiers of Medicine

Vol. 15 No. 4 August 2021

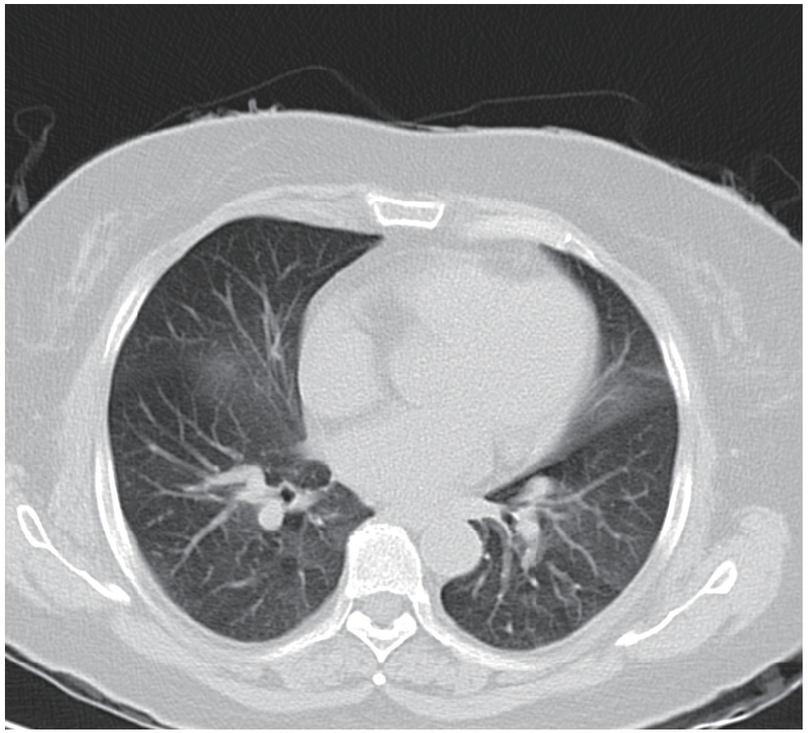

The CT scan shows pulmonary consolidation and inflammatory hyperplasia, which is considered to be a crucial mortality risk factor in Stevens–Johnson syndrome and toxic epidermal necrolysis. (Courtesy of Dr. Jinhua Xu. See pages 585-593 by Yanhong Shou *et al.* for more information.)

Available online
http://www.springerlink.com

CN 11-5983/R
邮发代号：**80-967**

ISSN 2095-0217

11684

FRONTIERS OF MEDICINE

Volume 15 ▪ Number 4 ▪ 2021 ▪ pp 507-648

Engineering
Transactions of CAE

ISSN 2095-0217
Volume 15 ▪ Number 4
August 2021
医学前沿

Frontiers of Medicine

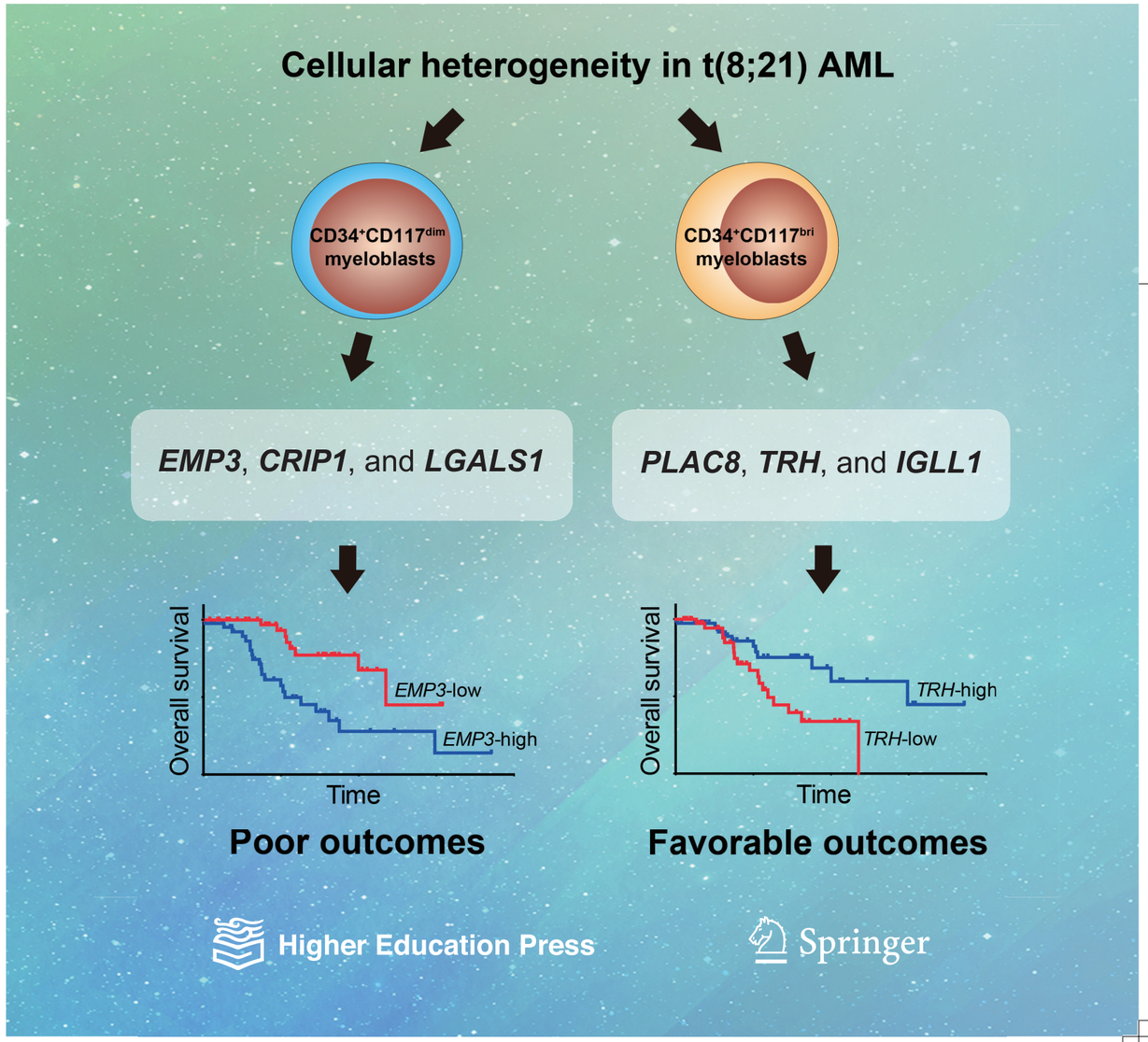

Higher Education Press
Springer

医学11-224-15-4.indd 1
2021/8/5 上午10:06